

## Original Research Article

# A comparative study of parapharyngeal space tumors over a 7 year period experience in tertiary care hospital

Athiyaman K.\*, Gowri Shankar M., Suresh V., Natarajan S., Malarvizhi R.

Department of ENT, Govt. Stanley Medical College Hospital, Chennai, Tamil Nadu, India

**Received:** 16 June 2018

**Revised:** 28 June 2018

**Accepted:** 02 July 2018

### \*Correspondence:

Dr. Athiyaman K.,

E-mail: athiyamankandasamy@gmail.com

**Copyright:** © the author(s), publisher and licensee Medip Academy. This is an open-access article distributed under the terms of the Creative Commons Attribution Non-Commercial License, which permits unrestricted non-commercial use, distribution, and reproduction in any medium, provided the original work is properly cited.

## ABSTRACT

**Background:** Tumors of the parapharyngeal space (PPS) are rare, accounting for 0.5–1.5% of all head and neck tumors. The anatomy of the PPS is responsible for a wide variety of tumors arising from the PPS. Our series of 10 PPS tumors provides an overview of the clinical course and management of PPS tumors.

**Methods:** This retrospective study included clinical data from patients treated for PPS tumors from 2011 to 2018 at the Stanley medical college hospital, Chennai.

**Results:** After careful analysis of the outcome of the study, we have found out that there was no local recurrence in any patient during the follow-up period. Though few approaches are advised in the literature, In our study transoral approach may be advocated as the first choice for excision of parapharyngeal space tumors, except for malignant tumors and neurogenic tumor. Trans cervical approach is used for malignant and neurogenic tumors, considering its advantages of providing direct access to the neoplasm, adequate control of neurovascular structures from the neck.

**Conclusions:** In our study, middle aged male population was most commonly affected. Pleomorphic adenoma is the most common PPS tumor; prestyloid compartment is mostly affected by these tumors. As per the previous studies, trans cervical approach is first choice for excision of parapharyngeal space tumors. In our study, trans oral approach is also a suitable, safe approach for pre styloid non vascular lesions and transcervical approach can be reserved for poststyloid and malignant lesions.

**Keywords:** Parapharyngeal space, Transcervical approach, Transoral approach, Diagnosis

## INTRODUCTION

The parapharyngeal space (PPS) is a triangular fat filled compartment of the suprahyoid neck, lateral to the pharynx. It is described as an inverted pyramid with the floor of the pyramid at the skull base and the apex at the level of the greater cornu of the hyoid bone.<sup>1</sup> There are several detailed anatomic descriptions in the literature. The styloid process along with the attaching muscles and tensor veli palatini fascia divides the PPS into a prestyloid and poststyloid compartment. The prestyloid space contains the deep parotid lobe and minor salivary glands. The poststyloid space contains the IX, X, XI and

XII cranial nerves, the cervical sympathetic chain, the internal jugular vein, the internal carotid artery and lymph nodes. This typical anatomy of the PPS is responsible for a wide variety of tumors arising from the PPS. Tumors of the PPS account for 0.5–1.5% of all head and neck tumors.<sup>2</sup> The majority is diagnosed in adults and includes primary neoplasms, direct extension from adjacent regions and metastatic disease. Approximately, 80% of these neoplasms are benign. Benign salivary gland tumors, and specifically pleomorphic adenoma, are most common, followed by neurogenic tumors. Salivary gland neoplasms are also the most frequently found primary malignant tumors.<sup>3</sup> Prestyloid tumors are commonly from salivary origin, while the poststyloid

space is most often affected by neurogenic tumors. PPS tumors may stay undetected for a long time because they initially develop without causing any symptoms. Symptoms generally occur when the tumor becomes larger than 2.5–3 cm. Imaging is crucial for the assessment of PPS tumors. Magnetic resonance (MRI), computed tomography (CT) with contrast and contrast angiography, in selected cases, are essential for diagnosis. MRI is preferred over CT because it provides more useful information on tumor localization and extension and distinguishes different tumor types as well as possible malignant characteristics and their relation to adjacent structures. Imaging also aids in preoperative planning. The cervical and the cervical—transparotid approach are generally used for surgical access. Under certain circumstances a cervical—transmandibular and combined transoral approach may be required. The risk of tumor spill is more likely if the access is limited, the tumor is large or in case of underestimation of the tumor's dimensions. Several supplementary procedures for a better access have been described, i.e., division of the stylomandibular ligament, removal or mobilization of the submandibular gland, excision of the lateral lobe of the parotid gland, extirpation of the styloid process and division of the posterior belly of the digastric muscle from the hyoid. Identification of the facial nerve and removal of the parotid tissue around the site of the origin will help to avoid tumor spill.<sup>4</sup> We examined the clinical data of 10 patients treated at the Stanley medical college hospital, Chennai which is a tertiary referral center for North Chennai with a population of about 5 millions for PPS tumors. This study is a follow-up study in the department of otorhinolaryngology, head and neck surgery of the said center.

There are several surgical approaches for the resection of PPS tumors. These are predominantly classified into four groups: Transcervical, transparotid, transoral and transmandibular approaches. These approaches, either done individually or as a combined approach, are performed in the surgery for PPS tumors depending on the characteristics of the tumor. In the present study, the diagnosis, surgical approach and complications associated with various surgical approaches for PPS tumors are discussed.<sup>5</sup>

## METHODS

The present, retrospective study included 10 patients who underwent surgery for primary PPS tumors between January 2011 and May 2018 in Stanley medical college hospital, Chennai. The protocol of the investigation was approved by the Institutional Review Board. Informed consent was obtained from the patients prior to their inclusion in the study.

### *Inclusion criteria*

All patients with parapharyngeal space tumors, age more than 20 yrs to 65 yrs included in our study.

### *Exclusion criteria*

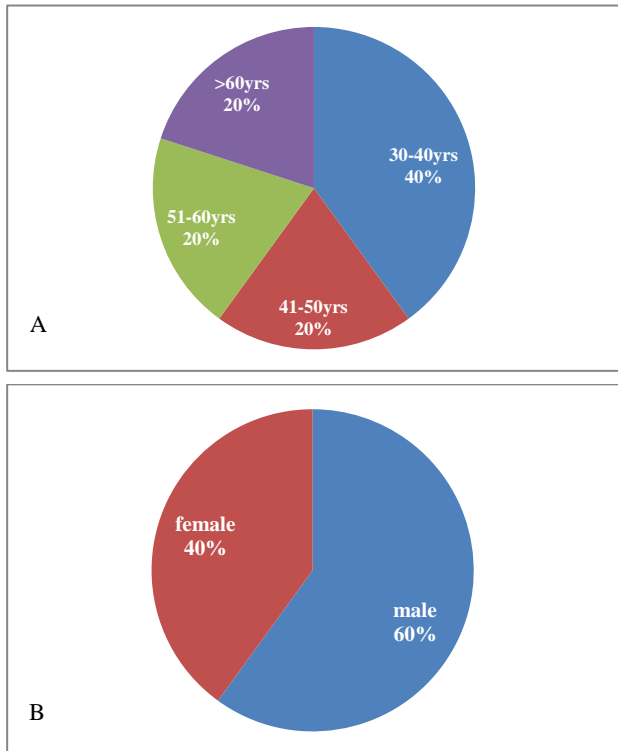
Patients with less than 20 yrs and more than 65 yrs, pts with comorbid condition like cardiovascular, neurological disorder were excluded in our study.

In regard to histological type, there was 1 case of neurogenic and 9 of salivary gland origin tumors. The following data were evaluated: Preoperative symptoms, histological type, surgical approach and complications. Patients were evaluated following a detailed clinical examination. Enhanced CT and MRI scans were used to confirm the location and size of the tumor as a preoperative diagnosis. In particular, the following aspects were evaluated: Tumor shape and the tumor margin, the association of the tumor location with major vasculature, surrounding tissue and the deep lobe of the parotid gland (DLPG), and whether the tumor localization was pre or poststyloid. Preoperative imaging was also used to estimate the origin of the tumor, the extent of malignancy and tumor vascularity. In the case of malignancy, additional imaging examination was performed to inform the selection of a treatment plan. Where tumors exhibited the possibility of paraganglioma, angiography or CT angiography was performed to evaluate the vasculature associated with the carotid artery for one case. For the examination of the histology of the tumor, fine needle aspiration cytology (FNAC) was performed in all the cases. All patients enrolled in the study underwent surgical treatment. The plan for the surgical approach was selected according to the tumor location, histological findings, the relationship to anatomical structures and the suspicion of malignancy.<sup>6</sup>

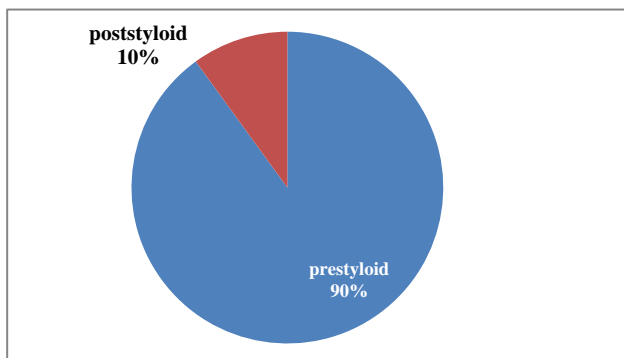
## RESULTS

There were 6 males and 4 females included in the present study. The mean age at the point of surgery was  $44.5 \pm 16.3$  years (range, 35-65 years). Pathological diagnosis resulted in 10 cases being classified as a neurogenic tumor 1 (10%) and 9 cases as a salivary gland tumor (90%) (Table 1). The most common symptoms of PPS tumors were a pharyngeal mass (37.5%), neck mass (20.5%), coughing (12.5%), hoarseness (12.5%) and pharyngeal pain (12.5%). The most common symptom of salivary gland tumors were the presence of a pharyngeal mass (80%) (Table 1). Preoperative CT or MRI imaging was used to evaluate the location of each tumor. A total of 7 salivary gland tumors were located in the prestyloid space and 1 case was located in the poststyloid space. The remaining case, a malignant parotid tumor, was occupying both the prestyloid and poststyloid spaces. One schwannoma case was in the poststyloid space. The size of each tumor was measured with CT or MRI imaging. In our study, the most frequent range for salivary tumor size was 40-100 mm (7 cases). The cytological examination revealed pleomorphic adenoma in 7 cases (84.6%), vagal schwannoma in 1 case and mucoepidermoid carcinoma in 2 cases. Two out of the ten patients who underwent a preoperative FNAC, the results

were suspicions of malignancy. Tumor resection was performed in all cases. For all patients with a benign tumor, the transoral, transcervical, transparotid or combined approach was selected. In patients with a malignant tumor, the mandibular swing approach was used to resect the tissues surrounding the tumor. The tumor was then exposed through the space between the submandibular gland and parotid gland. If approaching the tumor was difficult, the digastric posterior belly and stylohyoid muscle were cut. A microscope was used to improve the visibility of the area surrounding the tumor.



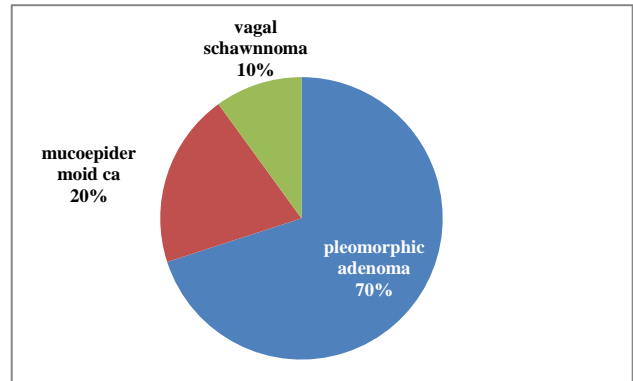
**Figure 1: Age distribution and distribution in our study. (A) Middle age and (B) Male affected most commonly in our study.**



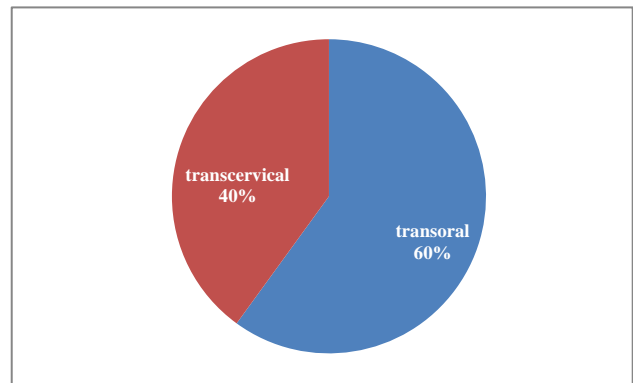
**Figure 2: Location of the PPS tumor in our study (prestyloid is most common location in our study).**

In cases of neurogenic tumor, the transcervical approach was used. A nerve integrity monitor was used for lower cranial nerve monitoring, including for the VII, IX, X, XI

and XII nerves. In schwannoma case, tumor enucleation was performed to preserve nerve functionality. In tumors of salivary gland origin, the transoral, transcervical, transparotid, mandibulotomy approaches were selected, according to tumor location. Out of 8 cases of benign tumors, 5 cases removed by transorally, 2 cases by transcervically, one by mandibulotomy approach. 2 cases of malignancy removed by trans cervically. Major complications following surgery are summarized in Table 2. In surgical removal of salivary gland tumors especially malignancy marginal mandibular nerve palsy was most common complication in our study.



**Figure 3: Histopathological examination in our study (pleomorphic adenoma most common tumor in our study).**



**Figure 4: Surgical approaches in our study (trans oral is most common in our study).**

**Table 1: Preoperative symptoms in parapharyngeal space tumors in our study.**

Symptom	N
Pharyngeal mass	7
Neck mass	4
Dysphagia	2
Earblock	2
Voice change	3
Snoring	1
FB sensation	2

**Table 2: Postoperative complications in PPS tumors in our study.**

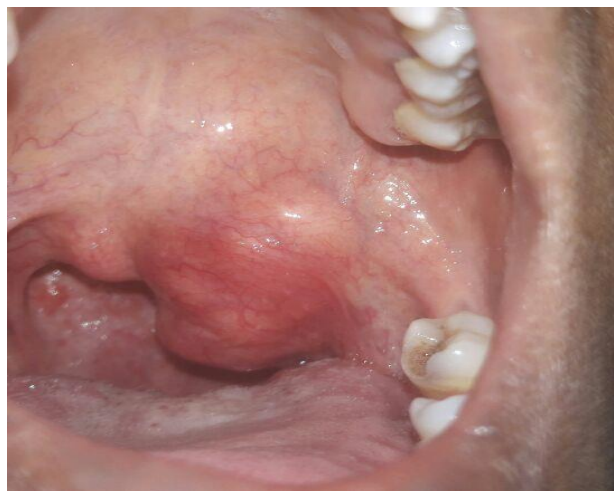Symptoms	n
Marginal mandibular nerve palsy	2
Pharyngeal pain	1
Wound infection	1

**DISCUSSION**

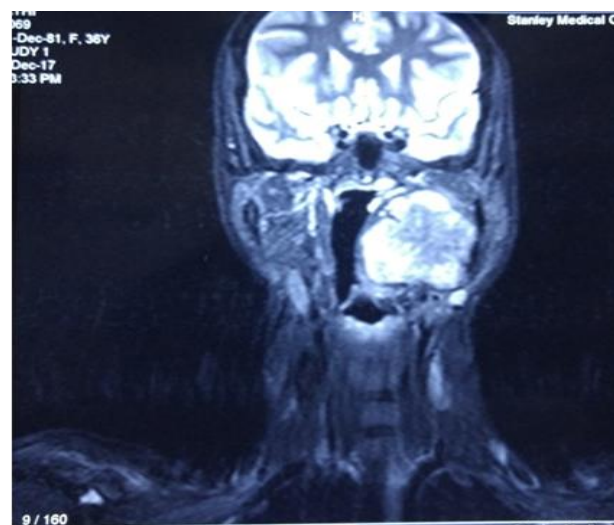PPS tumors occur deep within the neck, and this location results in difficulties in diagnosis and surgical treatment. According to previous reports, 70-90% of PPS tumors are benign. Only 2 cases (20%) of the cohort examined in the present study were malignant. Previous studies have reported that the most common subtype is pleomorphic adenoma originating from the deep lobe of the salivary gland, in our study also pleomorphic adenoma is most common tumor of PPS tumor.<sup>7</sup> The most frequent symptom in the cohort of the present study was a pharyngeal mass, followed by neck mass (Table 2) this is comparable with other studies. Dysphagia and pain have also been reported to be common symptoms. A previous study has reported that, for malignant tumors, the most frequent symptoms are a rapidly growing neck mass, pain, trismus, and otalgia and cranial nerve deficits. Malignant tumors in the present study presented with the symptom of a neck mass. Preoperative imaging analysis of the PPS is performed with the aim of providing information as follows: i) Size of tumor; ii) location of tumor (pre or poststyloid, relation to parotid gland) and iii) whether there is extension of the tumor to the adjacent area and major vasculature. MRI imaging is often able to provide this information for soft tissue. A previous study reported the superiority of MRI vs. CT as it permits the improved discrimination of soft tissue types. Enhanced CT is useful for analysis of tumor location and to preoperatively establish a method of approach for surgery. Three dimensional CT angiography is indicated when the tumor is suspected to be a carotid body tumor from its location, in order to evaluate its vascularity and confirm the diagnosis. It is also necessary to distinguish between benign and malignant tumors prior to surgery. In a previous study, cranial nerve palsy and pain were identified as symptoms likely to be associated with malignancy. Radiological signs of malignancy include irregular tumor margins, spread into surrounding tissues and fat planes as determined by CT or MRI, and evidence of enlarged, necrotic lymph nodes in the retropharyngeal and cervical area.<sup>8</sup>

A number of authors have described the indications for transoral, transparotid, transcervical or transmandibular approach to surgery. As per the previous studies, transcervical approach is the first choice for excision of parapharyngeal space tumors. In our study, transoral approach is also a suitable, safe approach for prestyloid nonvascular tumours and transcervical approach can be reserved for poststyloid and malignant lesions.<sup>9</sup> Tracheostomy is not ordinarily necessary for the surgery

of a benign PPS tumor. If a defect following tumor resection requires reconstruction with a musculocutaneous flap that may cause narrowing of the upper respiratory tract, tracheostomy is performed at the end of the surgery, as previously reported. In previous studies, the most frequently reported complication of PPS tumor surgery was mandibular branch of facial nerve palsy. These studies predominantly enrolled patients with a pleomorphic adenoma of the PPS.



**Figure 5: Smooth firm swelling in the left tonsillar fossa.**



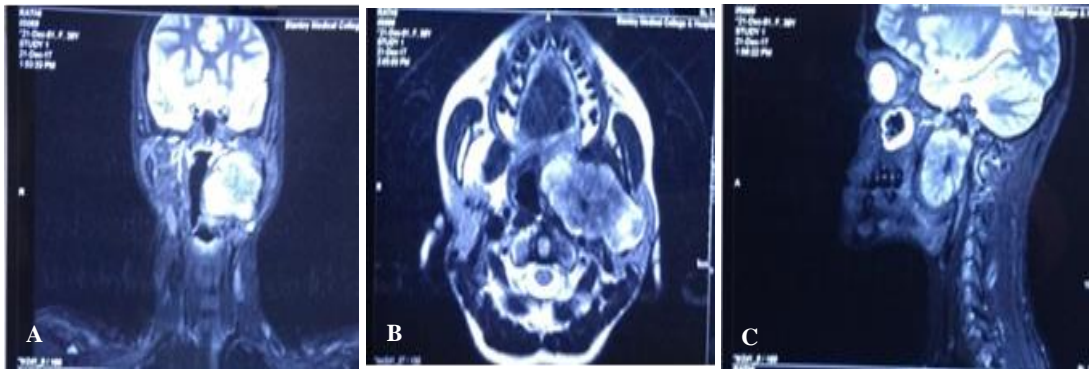
**Figure 6: CT of the pt shows well defined heterogeneous mass in prestyloid parapharyngeal space.**

In the cohort of the present study, mandibular branch of facial nerve palsy typically occurred following surgery to remove tumors of salivary origin (mucoepidermoid carcinoma), as the surgery was performed close to the mandible. The most serious complication of PPS tumor resection is cranial nerve paralysis. The associated cranial nerves are VII, IX, X, XI and XII. The cranial nerve from which tumor arises tends to be injured following the

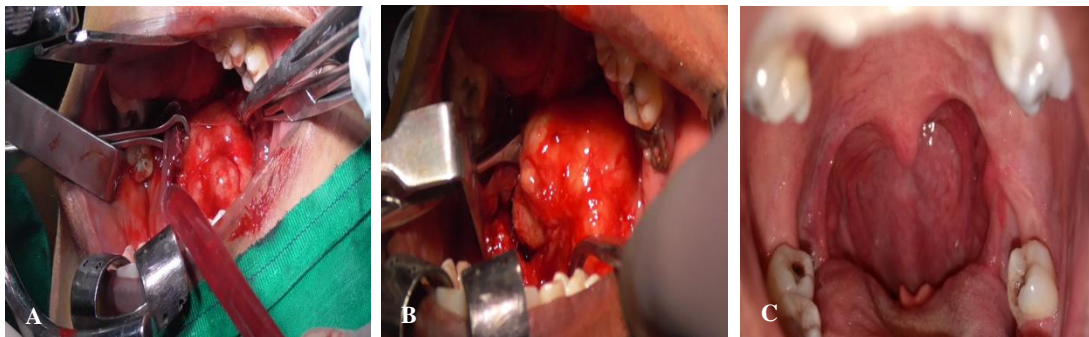
resection of neurogenic tumors, including schwannomas and paragangliomas. Cranial X palsy is the most common form, and may be severe following PPS surgery. A previous study revealed that neurogenic tumors, particularly vagal paragangliomas, are particularly at risk for developing post-operative sequelae. Horner syndrome may also be presented postoperatively in cases of sympathetic PPS schwannomas. The tumor enucleation of PPS schwannomas may allow the preservation of the function of the original nerves.<sup>10</sup> The strategy used during PPS surgery should be dependent on the status of the tumor. In the present study, this was determined with information obtained via clinical evaluation, imaging analysis and histological analysis. The most common histologic type was pleomorphic adenoma. When

pleomorphic adenomas are resected, tumor spillage should be avoided to prevent relapse.<sup>11</sup>

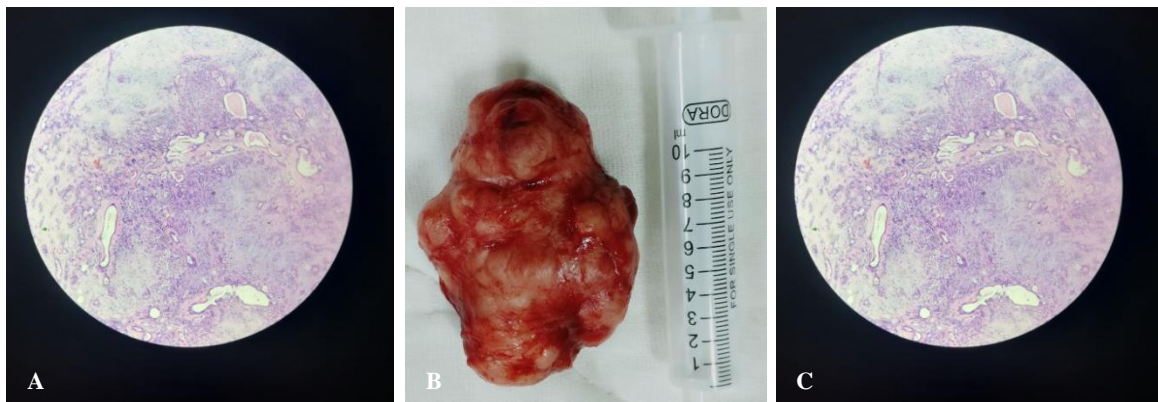The major goals of PPS tumor resection are to completely remove the tumor and reduce the number of postoperative complications. This may be achieved by improving the methods of examination, carefully selecting the approach for surgery and with accurate management during surgery. In our study transoral approach was most commonly used to remove benign nonvascular tumors without any perioperative and postoperative complications and without recurrence in 1 year follow up period. One of the four transcervically approached mucoepidermoid carcinoma patient had mandibular branch of facial nerve palsy.<sup>12</sup>



**Figure 7 (A-C): MRI shows 10\*5\*4 soft tissue swelling.**



**Figure 8: (A and B) Intraop and (C) postop 3 months after surgery.**



**Figure 9: HPE shows (A) preop FNAC, (B) postop biopsy macroscopic and (C) microscopic pleomorphic adenoma.**

## CONCLUSION

In our study, middle aged male population was most commonly affected. Pleomorphic adenoma is the most common PPS tumour and prestyloid compartment is mostly affected by these tumors. As per the previous studies, transcervical approach is the first choice for excision of parapharyngeal space tumors. In our study, transoral approach is also a suitable and safe approach for prestyloid nonvascular lesions and transcervical approach can be reserved for postsyloid and malignant lesions.

*Funding: No funding sources*

*Conflict of interest: None declared*

*Ethical approval: The study was approved by the Institutional Ethics Committee*

## REFERENCES

1. Stell PM, Mansfield AO, Stoney PJ. Surgical approaches to tumors of the parapharyngeal space. *Am J Otolaryngol.* 1985;6:92-7.
2. Basaran B, Polat B, Unsaler S, Ulasan M, Aslan I. Parapharyngeal space tumors: the efficiency of a transcervical approach without mandibulotomy through review of 44 cases. *Acta Otorhinolaryngol.* 2014;34:310-6.
3. Shahab R, Heliwell T, Jones AS. How we do it: a series of 114 primary pharyngeal space neoplasms. *Clin Otolaryngol.* 2005;30:364-7.
4. Cohen SM, Burkey BB, Netterville JL. Surgical management of parapharyngeal space masses. *Head Neck.* 2005;27:669-75.
5. Ducic Y, Oxford L, Pontius AT. Transoral approach to the superomedial parapharyngeal space. *Otolaryngol Head Neck Surg.* 2006;134:466-70.
6. Lawson VG, LeLiever WC, Makerewich LA. Unusual parapharyngeal lesions. *J Otolaryngol.* 1979;8:241-9.
7. Yu GH, Sack MJ, Baloch Z. Difficulties in the fine needle aspiration (FNA) diagnosis of schwannoma. *Cytopathology.* 1999;10:186-94.
8. Shahab R, Heliwell T and Jones AS: How we do it: A series of 114 primary pharyngeal space neoplasms. *Clin Otolaryngol.* 2005;30:364 -7.
9. Allison RS, Van der Waal, Snow GB. Parapharyngeal tumors: A review of 23 cases. *Clin Otolaryngol Allied Sci.* 1989;14:199-203.
10. Kuet ML, Kasbekar AV, Masterson L and Jani P: Management of tumors arising from the parapharyngeal space: A systematic review of 1,293 cases reported over 25 years. *Laryngoscope.* 2015;125:1372-81.
11. Som PM, Sacher M, Stollman AL. Common tumors of the parapharyngeal space: refined imaging diagnosis. *Radiology.* 1988;169:81-5.
12. Chang SS, Goldenberg D, Koch WM. Transcervical approach to benign parapharyngeal space tumors. *Ann Oto Rhino Laryngol.* 2012;121:620-4.

**Cite this article as:** Athiyaman K, Gowri Shankar M, Suresh V, Natarajan S, Malarvizhi R. A comparative study of parapharyngeal space tumors over a 7 year period experience in tertiary care hospital. *Int J Otorhinolaryngol Head Neck Surg* 2018;4:1167-72.