

## Original Research Article

# Comparative evaluation of conventional with endoscopy assisted nasal septal correction surgery in a tertiary care teaching hospital Trichy

Mohamed Anwar M.<sup>1\*</sup>, Jesudoss A.<sup>1</sup>, Thirumalaikolundusubramanian P.<sup>2</sup>

<sup>1</sup>Department of ENT, <sup>2</sup>Department of Medicine, Trichy SRM Medical College Hospital and Research Centre, Affiliated to The Tamilnadu Dr. M. G. R Medical University, Trichy, Tamil Nadu, India

**Received:** 13 June 2018

**Accepted:** 02 July 2018

### \*Correspondence:

Dr. Mohamed Anwar M,

E-mail: dranwarz@yahoo.com

**Copyright:** © the author(s), publisher and licensee Medip Academy. This is an open-access article distributed under the terms of the Creative Commons Attribution Non-Commercial License, which permits unrestricted non-commercial use, distribution, and reproduction in any medium, provided the original work is properly cited.

## ABSTRACT

**Background:** Nasal septal deviation is of both congenital and traumatic etiology, found among children and adults and many of whom require corrective surgery. Recently endoscopy assisted nasal septal correction surgery is being performed in many centers as a preferred one. Hence it was decided to find out the postoperative outcomes among those who underwent both the types of surgical procedures.

**Methods:** A total of 50 patients with septal deviation underwent conventional surgery and another 50 operated with endoscopy assisted method were considered for this study. Both groups were followed up for postoperative outcomes and relief of symptoms after 48 hours, 8 weeks and 24 weeks for statistical analysis.

**Results:** Head ache, watering of eyes and nasal obstruction were found significantly less in endoscopy assisted nasal septal correction during the first 48 hours and 8 weeks when compared with conventional surgery and it became negligible after 24 weeks of postoperative period.

**Conclusions:** Endoscopy assisted surgery is convenient in targeting the surgical site with less trauma and less requirement of time to perform the surgery. However, the initial cost would be higher for installation of endoscopy and maintenance.

**Keywords:** Nasal septal deviation, Conventional nasal septal correction method, Endoscopy assisted nasal septal correction surgery

## INTRODUCTION

Nasal septal deviation is associated with congenital and traumatic etiology and the nasal septal deviation has been reported both in the paediatric as well as in the adult population.<sup>1,2</sup> A significant number is reported to suffer from nasal septal deviation.<sup>2</sup> Happanemi reported that 9.5% incidence among children.<sup>3</sup> Nasal septal deformity (NSD) has adverse effect on the facial development. The prevalence of septal deformity ranges from 0.93% to 55% (Ilhami). There are different types of nasal septal deformities and the conventional method of surgery has been followed over years.<sup>1</sup> Recent days endoscope

assisted septal correction is gaining momentum as it provides a direct approach to the targeted site.<sup>4</sup>

Individuals with septal deformity develop nasal block, recurrent sinusitis, hyposmia, head ache, epistaxis, and occasional external disfigurement. Hence these cases require septal correction.

Endoscope assisted septal correction allows limited septal mucosal flap elevation and removal of cartilaginous and bony deformities, providing direct visual approach to the area of interest with limited but sufficient exposure.<sup>4</sup> There is no physical distortion of the nasal cavity unlike the use of rigid nasal speculum in the conventional

method. When combined with functional endoscopic sinus surgery, a single source of light with endoscope is sufficient for both the procedures instead of changing over to the head light in between. The surgical procedure can be transmitted through audio visual system, thus forming a good teaching tool and can be recorded and kept for further documentation. This study was undertaken to compare the conventional method of surgery with endoscope assisted septal correction in terms of complaints during the postoperative period, duration of hospital stay and comparison of relief in symptoms in both the groups.

**METHODS**

This study was conducted with 100 patients in the department of ENT, Trichy SRM Medical College Hospital and Research Centre, Trichy, after approval from the Institutional Research Board (IRB) and Institutional Ethical Committee (IEC). Patients with symptomatic nasal obstruction due to septal deviation in the age group of 18 to 60 years were selected after obtaining consent for conventional or Endoscope assisted septal correction procedure. They were randomly divided into two groups of 50 each. Group A (n=50) underwent septal correction using nasal endoscope and Group B (n=50) underwent conventional septal correction. The study was conducted from January 2016 to March 2017.

A detailed history was taken from all patients and a thorough clinical examination including nasal endoscopy was done after getting proper consent from the patients.

**Endoscope assisted septal correction**

All the cases were done under monitored anesthesia care, after giving Inj. Pethidine 1 mg per kg and Inj. Promethazine 0.5 mg per kg of body weight intramuscularly as premedication 45 minutes prior to the surgery

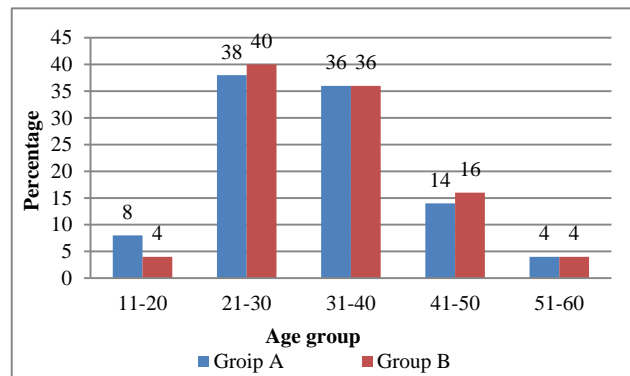
A 0° rigid endoscope of 4 mm diameter was used in the procedure. Injection 2% Lignocaine pre mixed with adrenaline in the concentration of 1 in 200000, not exceeding lignocaine 6 mg/kg body weight was given on both sides caudal to the deviated portion and incision at the convex side made caudal to the deformity. Using suction elevator, mucoperichondrial and mucoperiosteal flaps were elevated. Just posterior to the incision site, cartilage was incised in a slicing manner to avoid a through and through cut on the other side flap and the contra lateral mucoperichondrial and mucoperiosteal flaps elevated. Using Lucus forceps, the deviated septal cartilage was excised with due care to preserve the dorsal strip. Deviated portion of the vomer and perpendicular plate of ethmoid if any were removed. For septal spurs, incision was given parallel to the nasal floor on the summit of the spur and flaps were elevated both superiorly and inferiorly to expose the bony or cartilaginous spur and with an osteotome, chiseling out of

the bony protrusion done. Remnants of spur if any were trimmed with appropriate forceps.

Finally after thorough examination of the space between the two flaps for any left out bony or cartilaginous fragments in the depth, flaps were approximated and the nasal cavity was packed with small sized antibiotic soaked ribbon gauze. Septal suturing was done wherever possible. Packing was removed after 24 hours in both the type of patients. All patients were advised regular for follow up after 48 hours, 8 weeks, and 24 weeks subjective assessment of nasal patency and objective endoscopic examination. The data was collected, tabulated and entered in the SPSS software. Analysis was done with descriptive statistics and fishers exact probability test was done to find out significance among conventional and endoscope assisted nasal septal correction surgery.<sup>5</sup>

**RESULTS**

The mean age of Group A and B were 31.32 and 32.22 respectively. The standard deviation of the two groups was ±9.068 and ±9.188 which showed that the two groups were almost identical. The minimum and maximum age of group of A was 18 and 60 and group B was 18 and 53.



**Figure 1: Age group of study population.**

The group stratification showed all age groups were almost identical except the percentage of age group 11-20 in Group A was 8% (conventional) and Group B was 4% and the details are shown in Figure 1.

The overall gender ratio between female and male was 1:1.3 as furnished in Table 1.

In the pre-operative period nasal block was the main complaint among 90% of the patients, the duration varying from 6 to 24 months in group A and 6 to 18 months in group B with an mean of 10.4 months in group A and 8.92 months in group B. Pain during surgery and in the postoperative period was enquired as per pain scale<sup>6</sup> Per operatively the average for perception of pain was found to be 7.4 for conventional group and 2.2 for endoscopic group. Postoperatively the average for

perception of pain with pack was found to be 8 for conventional group and 2.2 for endoscopic group. Comparison of complaints with pack in postoperative period was shown in Table 2. There was statistically significant difference between the two groups regarding

all complaints after 1 week of surgery. Comparison in the relief of symptoms at the end of 8 weeks is shown in Table 4. In conventional group 10 (20%) developed synechiae whereas in endoscopic group only 2 (4%) developed synechiae.

**Table 1: Comparison of age and sex in group A and B.**

Group A (endoscope assisted)			Group B (conventional)		
	Minimum age in years	Maximum age in years		Minimum age in years	Maximum age in years
<b>Male n=25</b>	18	53	Male n=27	18	60
<b>Female n=25</b>	21	50	Female n=23	19	43

**Table 2: Comparison of complaints with pack in 48 hours after postoperative period**

Sl. No	Complaints	Group A (endoscope assisted) (n=50) (%)	Group B (conventional) (n=50) (%)	P value
<b>1</b>	<b>Headache</b>	10 (20)	25 (50)	0.0152
<b>2</b>	<b>Watering of eyes</b>	08 (16)	20 (40)	0.0134
<b>3</b>	<b>Nasal pain</b>	02 (04)	10 (20)	0.2687

**Table 3: Duration of hospital stay**

Sl. No	Duration	Group A (endoscope assisted) (n=50)	Group B (conventional) (n=50) (%)	P value
<b>1</b>	<b>More than 48 hours</b>	02 (04)	08 (16)	0.0916

**Table 4: Comparison of relief in symptoms in Group A and B after 8 weeks**

Symptoms	Group A (endoscope assisted) (n=50)	Group B (conventional) (n=50)	P value
<b>Nasal obstruction</b>	48 (96)	40 (80)	0.0277
<b>Headache</b>	49 (98)	36 (72)	0.0004

**Table 5: Comparison of relief in symptoms in both the groups after 24 weeks in Group A and B**

Symptoms	Group A (endoscope assisted) (n=50)		Group B (conventional) (n=50)		P value
	No (%)	Yes (%)	No (%)	Yes (%)	
<b>Nasal obstruction</b>	48 (96)	2 (4)	46 (92)	4 (8)	0.6777
<b>Headache</b>	49 (98)	1 (2)	48 (96)	2 (4)	1.000

The complaints of presence of head ache, watering of eyes and nasal pain were recorded after 24 hours of postoperative period in Group A & B. The presence of head ache among the postoperative patients was significantly less group A when compared with group B (p<0.05). Likewise the watering of eyes (p=0.0134) and nasal pain (p=0.0277) were also significantly less reported in group A, and the details are provided in Table 2.

As most of the group A and B were not required hospitalization for critical observation, the postoperative patients were discharged after period of 48 hours and very few patients with edema and epistaxis were allowed to stay more than 48 hours for observation. The hospital stay for both the groups did not vary significantly

(p>0.05). The details of hospital stay were given in Table 3.

Patients of both the groups were reviewed after eight weeks of postoperative period and the symptoms of nasal obstruction and presence of head ache were elicited. In Endoscope assisted postoperative patients, the presence of nasal obstruction and head ache were found in less numbers when compared with conventional surgical procedure. The difference among group A and B were significantly less (p<0.05) in number in group A as furnished in Table 4.

The follow up after 24 weeks revealed almost identical cure among both the groups without any statistical

significance ( $p>0.05$ ), and the details are given in Table 5.

## DISCUSSION

Desormeaux has developed and credited for the invention of first endoscope.<sup>7</sup> Later on so many advancements made in endoscopes and being utilized for the modern surgery.<sup>8-10</sup>

Since the 1960s Nasal endoscopy has been in use to generate a two-dimensional anatomical view of the nasopharyngeal region.<sup>11</sup> Endoscopy is a safe and quick to perform procedure. These endoscopes are being used as diagnostic and therapeutic tool. Nowadays endoscopes are used frequently for the diagnosis and treatment purposes in otology and skull base surgery, as well as diseases and surgeries of gastrointestinal tract, respiratory tract, urinary tract, and female reproductive tract. Apart from that, endoscopes are also used for laparoscopy, arthroscopy, thorscopy, and mediastinoscopy.

Nasal endoscopy is moderately sensitive and highly predicting the CT scans results as per Rosebe.<sup>12</sup> Ogino–Nishimura et al report that endoscopy has given 89% better under shading of the anatomy, 75.3% disease complications, and 83.6% reported to want to use endoscope. Kennedy<sup>13</sup> has reported that endoscopic surgery enabled technological advances in understanding disease pathogenesis and management. Bliss et al reported that this new technology was appreciated by all the otorhinolaryngologists and across many specialities.<sup>11</sup> In a study conducted by Gulati et al has reported that postoperative complaints of headache, watering of eyes and swelling of face were 24%, 16% and 12% respectively in endoscope assisted nasal septal correction surgery the same findings were also found in this study.<sup>4</sup> This study concurs with the findings of symptoms in the conventional surgery also. However Bothra and Mathur did not record any significant difference between the conventional and endoscopy assisted nasal septal correction surgery as the sample size was small. In this study the follow up has been extended to 8 weeks and 24 weeks to study the symptoms.<sup>14</sup> In endoscope assisted surgery the symptoms considerably reduced significantly when compared with conventional surgery after 8 weeks. However, after 24 weeks in both the methods the variation in symptoms was not significantly prominent. When the other aspects in both the types of surgery were considered, there were documentation of pros and cons. Light pack is sufficient in endoscope method whereas tight pack is essential in conventional method. Extra man power is required in endoscope method and cost of surgery is comparatively less in conventional method than surgery performed by endoscope and trained and professionally skilled surgeon is essential to perform surgery with endoscope. Initial establishment and maintenance is also more in performing endoscopic methods. On the contrary synechia formation is little more in conventional method and little more

postoperative hospital stay time required when compared with endoscope assisted nasal septal surgery.

## CONCLUSION

Endoscopy assisted nasal septal correction surgery is overweighed on conventional surgery as this technique is capable of approaching the targeted site more precisely and corrective surgery would be performed in less time with more accuracy even though the establishment expenditure is costlier than conventional nasal septal corrective surgery. Earlier relief from postoperative symptoms is significantly more in endoscopy assisted nasal septal correction surgery.

## ACKNOWLEDGMENTS

The authors gratefully acknowledge Thiru M. Ismail Research coordinator Trichy SRM Medical College Hospital and Research Centre, Trichy for the manuscript preparation and arrangements made for publication.

*Funding: No funding sources*

*Conflict of interest: None declared*

*Ethical approval: The study was approved by the Institutional Ethics Committee*

## REFERENCES

1. Neskey D, Eloy JA, Casiano RR. Nasal, septal and turbinate anatomy and embryology. *Otolaryngol Clin N Am.* 2009;42:193–205.
2. Reitzen SD, Chung W, Shah AR. Nasal septal deviation in the pediatric and adult populations. *Ear Nose Throat J.* 2011;90(3):112-5.
3. Haapaniemi JJ, Suonpää JT, Salmivalli AJ, Tuominen J. Prevalence of septal deviations in school-aged children. *Rhinology.* 1995;33(1):1-3.
4. Gulati SP, Wadhwa R, Ahuja N. Comparative evaluation of endoscopic with conventional septal correction. *Indian J Otolaryngol Head Neck Surg.* 2009;61(1):27-9.
5. Hwang PH, Mclaughlin RB, Lanza DC, KennedyDW. Endoscopic septal correction: Indications, technique, and results. *Otolaryngol Head Neck Surg.* 1999;120(5):678-82.
6. Polomano RC, Galloway KT, Kent ML, Brandon-Edwards H, Kyung BC, Kwon N, et al. Psychometric Testing of the Defense and Veterans Pain Rating Scale (DVPRS): A New Pain Scale for Military Population. *Pain Med.* 2016;17(8):1506-19.
7. Schmitt PJ, Jane JA Jr. A lesson in history: the evolution of endoscopic third ventriculostomy. *Neurosurg Focus.* 2012;33(2):1-5.
8. Antoniou SA, Antoniou GA, Koutras C, Antoniou AI. Endoscopy and laparoscopy: a historical aspect of medical terminology. *Surg Endosc.* 2012;26:3650–4.

9. Lau WY, Leow CK, Li AKC. History of Endoscopic and Laparoscopic Surgery. *World J Surg.* 1997;21:444–53.
10. Ogino-Nishimura E, Nakagawa T, Sakamoto T, Ito J. Efficacy of three-dimensional endoscopy in endonasal surgery. *Auris Nasus Larynx.* 2015;42:203–7.
11. Bliss M, Muntz H. Nasal Endoscopy: New Tools and Technology for Accurate Assessment. *Adv Otorhinolaryngol.* 2015;76:18-26.
12. Rosbe KW, Jones KR. Usefulness of patient symptoms and nasal endoscopy in the diagnosis of chronic sinusitis. *Am J Rhinol.* 1998;12(3):167-71.
13. Kennedy DW. Technical innovations and the evolution of endoscopic sinus surgery. *Ann Otol Rhinol Laryngol.* 2006;196:3-12.
14. Bothra R, Mathur N. Comparative evaluation of conventional versus endoscopic septoplasty for limited septal deviation and spur. *J Laryngol Otol.* 2009;123:737–41.

**Cite this article as:** Mohamed Anwar M, Jesudoss A, Thirumalaikolundusubramanian P. Comparative evaluation of conventional with endoscopy assisted nasal septal correction surgery in a tertiary care teaching hospital Trichy. *Int J Otorhinolaryngol Head Neck Surg* 2018;4:1151-5.